



**STANISLAUS COUNTY SHERIFF'S DEPARTMENT  
CORONER'S DIVISION  
939 OAKDALE ROAD  
MODESTO, CA 95355  
(209)567-4500**

**CORONER CASE NUMBER:** 09-04-24  
**ACCESSION NUMBER:** SA09-000173  
**NAME:** PRESCOTT, Craig  
**AGE:** 38 years  
**RACE:** Black  
**SEX:** Male  
**HEIGHT:** 69 inches  
**WEIGHT:** 256 pounds (estimated)  
**DATE AND TIME OF DEATH:** 04/13/2009 @ 1120  
**PLACE OF DEATH:** Doctors Medical Center – IP  
**DATE AND TIME OF AUTOPSY:** 04/14/2009 @ 0940  
**PLACE OF AUTOPSY:** STANISLAUS COUNTY CORONER'S OFFICE  
**PROSECTOR:** EUGENE CARPENTER, JR., M.D.

**WITNESSES:**

1. Mike Hermosa, DA's Office
2. Ana Morales, ID, S/O
3. Ken Hendrick, Detective, S/O

**HISTORY OF DEATH:**

Please see investigator's report.

**EXTERNAL EXAMINATION FOR IDENTIFICATION AND FOR SIGNS OF NATURAL PATHOLOGY:**

The body is that of a 38-year-old, well-developed, moderately to severely obese African American man about 69 inches in length and weighing about 256 pounds. It has been refrigerated and is not embalmed. It is identified by identification bands.

**MAJOR IDENTIFYING CHARACTERISTICS:**

1. The head hair is black with gray, tightly curled and about 2 inches in length.
2. The eyes are brown.

CONFIDENTIAL DOCUMENT

DUPPLICATION OR REISSUANCE  
CONTROLLED BY LAW

Released to Opt. Beck

**AUTOPSY REPORT**

By EH Date 6/3/09

3. The teeth are natural.
4. No surgical scars are seen.
5. Wrist scars, needle track scars, deformities and amputations are not seen.
6. The penis is circumcised.
7. The face appears unshaven for one to two days.
8. Whether or not mustache and beard are present is not noted.

The skin, head, head hair, eyes, ears, nose, mouth, throat, neck, chest, abdomen, pelvis with external genitalia and anus, back and extremities are unremarkable except for the moderate to severe obesity.

**CLOTHING:**

Clothing is not examined. This was a hospitalized case.

**EVIDENCE OF POSTMORTEM CHANGES:**

1. Rigor mortis is full.
2. Lividity is posterior and prominent.
3. Signs of decomposition are lacking. The body is in a very fresh state.

**EVIDENCE OF MEDICAL INTERVENTION:**

1. Properly placed nasogastric tube.
2. Properly placed endotracheal tube.
3. A line is present at the inferior lateral right collar bone.
4. An IV line is present at the antecubital fossa on the right.
5. An IV line is at the right wrist.
6. An IV line is at the back of the left hand.
7. There is a urinary catheter tube present in proper position.
8. Subcutaneously and underneath the muscle of the mid anterior chest there are areas of hemorrhage. On the right upper front chest, 3 inches below the top of the head and 3 inches right of the midline, there is an area of hemorrhage over the rib cage that is 2-1/2 x 1-1/2 inches. This area of hemorrhage overlies a nondisplaced complete fracture of the third rib. Below

CONTROLLED DOCUMENT

DUPLICATION OR REISSUANCE

CONTROLLED BY LAW

Released to Cpt Back

By SH Date 6/3/09

---

**AUTOPSY REPORT**

and to the right at the lateral right chest at the anterior axillary line there are two, 3/4 inch areas of external chest wall hemorrhage over the fourth and fifth ribs but no fractures are felt.

9. Three inches below the top of the head and 2-1/2 inches to the left of the midline there is a 1-1/2 x 3/4 inch area of hemorrhage at the external chest wall underneath the skin, subcutaneous fat and muscle of the chest wall. Underlying this area of hemorrhage is again a nondisplaced fracture of the third rib. Below and to the left of that very similar and with symmetry to the right side of the chest, there is a 2 x 3 inch area of hemorrhage over the external chest wall and there is a fracture of the fifth lateral rib at the anterior axillary line.
10. All of the above injuries are consistent with cardiopulmonary resuscitation and are not consistent with an assault.
11. One additional area of hemorrhage, 1 x 3/4 inch, is seen at the anterior lower right chest as diagramed.
12. The underlying mediastinal tissues, pericardial sac, pericardial fluid and heart are free of signs of injury.

**EVIDENCE COLLECTED AT AUTOPSY:**

1. Blood, vitreous, bile, urine and tissues from the major organs are collected.
2. Also in anticipation of the need of brain for special studies, coronal sections of the left hemisphere of the brain are collected. However, because of the body being on the respirator for about eight hours, researchers are contacted and mentioned that the samples are not adequate. These brain samples are returned to the organ bag in the body.

**TATTOOS:**

No tattoos are noted.

**RADIOGRAPHS:**

Numerous radiographs, basically a body survey, are available for review on the computer screen. These are reviewed and signs of long bone fractures are not seen. Chest fractures are not seen. This is consistent with the hairline nature of the rib fractures.

**INCISIONS:**

1. Head, coronal.
2. Chest, Y-shaped.
3. Abdomen, midline.

CONTROLLED DOCUMENT

DUPLICATION OR REISSUANCE  
CONTROLLED BY LAW

Released to Cpt Beck

**AUTOPSY REPORT**

By elt Date 6/3/09

**EXAMINATION AND DESCRIPTION OF INJURIES:**

1. Head: The head is carefully examined and the external head, subgaleal head and the brain are all unremarkable without signs of injury. This is referring to blunt force injury. The brain is swollen consistent with hypoxic injury.
2. Central face: There are no signs of injury to the central face.
3. Throat/neck: There are no signs of injury to the throat/neck region. The small bones of the throat are intact. There are no signs of bruising. There are no fingernail marks or bruises on the external throat. There are no signs of hard ligature marks to the throat.
4. Chest: The chest is unremarkable. The chest is carefully inspected for any sign or Taser needle injury. No such signs are seen. The chest is thoroughly inspected front and back.

There are numerous circular lesions across the upper back. There are about six such injuries. Similar injuries are seen at the left buttock and left upper extremity. Those at the left upper back are typical and consist of circular lesions further characterized by a circular central island of intact skin surrounded by abrasion. The areas of injury are about 1/2 to 3/4 inch. The central circular skin is about 1/4 inch. These injuries are unique and consistent with the history of nonlethal weaponry. About five such injuries are seen at the upper left back. About four such injuries are seen at the back and side of the left upper arm. About two injuries are seen at the left lower forearm and hand, and about three injuries are present at the left buttock area.

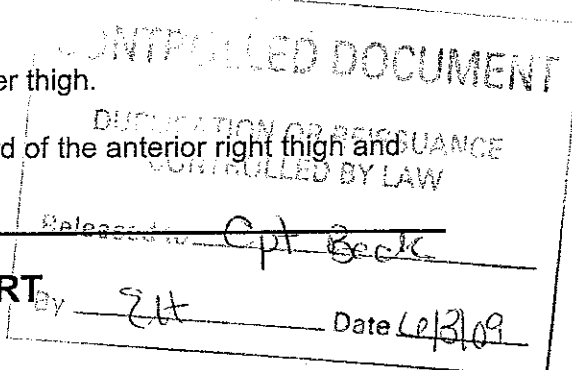
5. Abdomen: Unremarkable.
6. Pelvis with external genitalia and anus: The nonlethal blunt force injuries have been previously described. These occur at the left buttock region.
7. Back: See Chest description.
8. Extremities: See Chest description. Also there are linear healing abrasions across each wrist and across the ankles consistent with minor injuries from restraint procedures.

**SEARCH FOR POSSIBLE TASER WOUNDS:**

1. There is 1/8 inch scabbed lesion at the lower one-third of the dorsal right forearm.
2. There is a 1/8 inch area at the left lateral upper thigh.
3. There is a 1/8 inch area at the middle one-third of the anterior right thigh and

**AUTOPSY REPORT**

By ZH Date 6/2/09



adjacent to it is a cross-pattern of minor injury. This is just above the old but prominent abrasions across the lower one-third of the anterior lateral right thigh. Once again no signs of similar injuries are seen at the chest, front or back. In this regard the fat pad of the abdomen and the chest wall is measured and at the level of the navel at the midline it is 5 cm. About 6 inches higher it is 4 cm. At the epigastric region it is 3 cm. The fat pad at the upper anterior chest on both sides at the mid clavicular line is 3 cm. No subcutaneous hemorrhages are seen nor is any hemorrhage seen in the fat pad. The areas inspected are along the midline abdominal incision and the Y-shaped chest incision.

4. Petechial hemorrhages are not seen at the eyes.

#### INTERNAL EXAMINATION FOR SIGNS OF NATURAL PATHOLOGY:

##### BODY CAVITIES:

The cavities of the head, chest, abdomen and pelvis are unremarkable for signs of natural pathology except the brain has signs of being swollen. There are no herniation signs of the brain. Pleural effusions are not seen.

##### SYSTEMS:

##### Central Nervous:

The brain is consistent with being a respirator brain. It is extremely soft and friable. The estimated weight is about 1500 grams. The brain is not weighed because of the danger of it tearing. Special studies are planned and tearing of the brain is not an option. The gyri are flattened universally. There are no signs of brain herniation. Other than the extreme softness and signs of swelling of the brain, the brain with its meninges, cerebral cortex, white matter, central nuclei, brain stem, cerebellum, cranial nerves and blood vessels is unremarkable. The spinal cord is not dissected. A separate stock jar filled with formalin is used to save large sections of the important areas of the brain. These sections come from the right hemisphere. Sections are not submitted for histology.

##### Cardiovascular:

The heart is enlarged. It is 500 grams. This is due to left ventricular wall hypertrophy. The septum is 2 cm thick as is the posterior and anterior walls of the left ventricle. The enlargement and thickening is symmetrical. There are no signs of an aortic outflow obstruction. The mitral valve is 11 cm, the aortic valve 8 cm, the pulmonary valve is 8 cm, and the tricuspid valve is 14 cm. The tricuspid valve opened width of 14 cm is consistent with dilatation of the right side of the heart. Other than the enlargement of the heart, there is evidence of disease in the coronary arteries. There is diffuse atherosclerosis for about 30% of the length of the right and left coronary arteries. It is patchy. Diffusely only about 10% of the luminal space is compromised. In addition to diffuse thickening in segmental areas, there are several foci of 30% atherosclerotic occlusion. One area has a 50% atherosclerotic occlusion and this is in

## AUTOPSY REPORT

Released to: Cpt Beck

By: Elt Date: 6/3/09

the proximal left anterior descending branch of the left main coronary artery. Signs of thrombosis are lacking. Signs of calcification are lacking. Other than the enlargement and mild to moderate atherosclerosis the heart with its pericardial sac, pericardial fluid, epicardium and coronary arteries, myocardium, endocardium and valves is unremarkable. The aorta with its branches, the vena cava with its tributaries and the pulmonary arteries are unremarkable. There are no signs of thromboemboli.

**Respiratory:**

The airway is clear and free of signs of inflammation. The right lung is very heavy at 800 grams. The left lung is moderately heavy at 600 grams. Other than being wet, heavy and congested the lungs are unremarkable. There are no signs of inflammation.

**Gastrointestinal:**

The GI tract, 2500 gram liver, gallbladder and pancreas are unremarkable except for the moderate hyperplasia of the liver. Fatty change and cirrhosis cannot be seen in the cut section of the liver.

**Lymphoid:**

The spleen is mildly enlarged. Otherwise the thymus, spleen and lymph nodes are unremarkable. The spleen is 190 grams.

**Genitourinary:**

The kidneys are hyperplastic. Together they are 520 grams. They are equal in size. The surfaces are smooth. Other than the severe hyperplasia, the kidneys, urinary bladder, prostate and testicles are unremarkable. The prostate and testicles are examined by palpation.

**Endocrine:**

The thyroid and adrenal glands are unremarkable.

**Musculoskeletal:**

Unremarkable.

**TOXICOLOGY:**

A comprehensive toxicology screen is requested. Special testing for Ativan is requested.

Toxicology is non-contributory. No medications or drugs are detected.

CONTROLLED DOCUMENT

DUPPLICATION OR REISSUANCE  
CONTROLLED BY LAW

Released to Cpt. Beck

**AUTOPSY REPORT**

By EH Date 6/3/09

**MICROSCOPIC:**

Slide Key:

1. Pancreas; thyroid
2. Lung
3. Kidney, spleen, liver
4. Heart
5. Lung
6. Adrenal; kidney
7. Heart
8. Heart

**FINDINGS:** The heart sections have hypertrophic nuclear changes and prominent patches of interstitial fibrosis (7, 8). The lungs have signs of congestion and mild edema.

**IMPRESSION:**

1. Hypertrophic heart disease
2. Cardiac interstitial fibrosis

**DIAGNOSES:**

1. **History of chronic hypertension**
2. **Hypertensive heart disease**
3. **Mild to moderate atherosclerosis of the coronary arteries**
4. **Heavy, wet and congested lungs, no signs of pneumonia**
5. **Swelling of the brain consistent with hypoxic encephalopathy and respirator brain, no signs of brain stem herniation**
6. **Status post employment of nonlethal weaponry consisting of Tasers and nonlethal projectiles, no clear Taser marks seen at the chest, front or back, there are a few wounds on the extremities consistent with Taser devices, and circular abrasions consistent with nonlethal projectile use**
7. **No signs of head or throat trauma**
8. **Signs of mild injury at the wrists and ankles consistent with restraint procedures**
9. **Status post hospital/medical attention including administration of Ativan**

CONTROLLED DOCUMENT

DUPPLICATION OR REISSUANCE  
CONTROLLED BY LAW

Released to Cpt. Beck

By EA Date 6/3/09

---

**AUTOPSY REPORT**

- 10. Past history of recreational drug use, types of drugs not known
- 11. Past history of violent psychotic behavior; depressive disorder, possible bipolar disorder; chronic high blood pressure; possible mild chronic kidney disease; past history of heavy alcohol intake

**CAUSE OF DEATH:** Hypertensive heart disease, years

**OTHER CONDITIONS CONTRIBUTING TO DEATH:** Psychotic behavior; moderate cardiovascular strain from heightened physical activity; chronic interstitial fibrosis of the heart; atherosclerotic coronary artery disease

The autopsy is completed on 04/14/09 at 1230.

*E. C. J. MD*  
\_\_\_\_\_  
Eugene Carpenter, Jr., M.D.  
*5-12-09*

CONTROLLED DOCUMENT  
DUPLICATION OR REISSUANCE  
CONTROLLED BY LAW  
Released to Cpt Brock  
By EH Date 4/3/09

---

**AUTOPSY REPORT**



**Case Name:**

Prescott,

Craig

**TOXICOLOGY NUMBER:** CVT-09-5049

**Specimen Description:**

Hospital sample: 1 ml blood (1 vial) labeled "Medical, Lily; 11Apr09; 1430 hrs; (0000) 000850198; Prescott, Craig; 09-04-24" Postmortem samples: 9.5 ml (R) femoral blood (gray top vial), 9.5 ml heart blood (gray top vial) & 1 ml urine each labeled "Prescott, Craig; 09-04-24"

**Delivered by** Tricor

**Date** 16-Apr-09

**Received by** Bill Posey

**Date** 16-Apr-09

**Request:** Complete Drug Screen

**Agency Case #** 09-04-24

**Requesting Agency**

Stanislaus County Sheriff/Coroner  
Attn: Sheriff's Administration Finance  
250 Hackett Rd.  
Modesto CA 95358

**Report To**

Stanislaus County Sheriff/Coroner  
Attn: Dr. Carpenter  
939 Oakdale Rd.  
Modesto CA 95355

**RESULTS**

Specimen: Hospital Blood Sample

Complete Drug Screen: No common acidic, neutral or basic drugs detected.  
No Lorazepam detected. No blood Ethyl Alcohol detected.

CONTROLLED DOCUMENT  
DUPLICATION OR REISSUANCE  
CONTROLLED BY LAW  
Released to Cpt Beck  
By ELH Date 6/3/09

**Analyst**

B. L. Posey

April 27, 2009

**B.L. POSEY**  
**S.N. KIMBLE**  
*Directors*

1580 Tollhouse Road  
Clovis, California 93611  
Phone (559) 323-9940  
Fax (559) 323-7502

**SHERIFF'S DEPARTMENT**  
**County of Stanislaus**

DATE 4/23/09	O T	INCIDENT REPORT	FOLLOW-UP REPORT	FILE NO. S09-15518
-----------------	--------	--------------------	---------------------	-----------------------

VICTIM (AS LISTED ON ORIGINAL REPORT) PRESCOTT, CRAIG EDWARD	LOCATION OF OCCURRENCE DOCTORS MEDICAL CENTER, MODESTO, CA
---	---

**CORONER'S REPORT #09-04-24**

**CONTROLLED DOCUMENT**

DUPLICATION OR REISSUANCE  
 CONTROLLED BY LAW

Released to Cpt. Beck

By EH Date 4/23/09

**SYNOPSIS:**

**CORONER'S REPORT: IN CUSTODY DEATH**

**NARRATIVE:**

On 4/13/09 Stanislaus County Sheriff Deputy Coroner Tiffani Mende referred this case to me as she was leaving for the day. Deputy Mende informed me the decedent had been pronounced brain dead twice but was being kept on a ventilator pending arrival of his family. At 1300 hours, I contacted Tracy, a registered nurse at Doctor's Medical Center (DMC). She advised me that she had information to contact the decedent's wife, Rachel Prescott, and would get her to the hospital to be notified. I requested the decedent's admission blood be placed on hold. I also requested medical records at that time. Tracy confirmed the decedent was being kept on a ventilator as they were waiting for the decedent's family to arrive.

At 1443 hours, I spoke to Kathy, a registered nurse at DMC, and was advised that Rachel Prescott was on her way. Kathy informed me a representative from California Transplant Donor Network (CTDN) was following the decedent's case and would most likely want to speak with me regarding authorization for organ and tissue donation. I then reviewed the case with Dr. Carpenter, who advised against organ and tissue donation. He stated that in cases involving electronic control devices it can be difficult to find a cause of death. Dr. Carpenter requested organ and tissue donation be declined. Sgt. Ray Harper was contacted at the Stanislaus County Men's Jail and he also requested that organ and tissues donation be declined due to the fact that the decedent was in custody when the incident occurred.

At 1830 hours, I was contacted by Kathy at DMC, who stated that the decedent's family had arrived was advised of the decedent's condition. She stated the medical staff was preparing to discontinue ventilation. Kathy advised me the decedent would be transported to the holding area once ventilation was discontinued and his family had left. I requested she contact me when the decedent was being transported so I could meet the security guard at the holding area to receive the decedent. Kathy informed me a Stanislaus County Sheriff's Deputy had been posted as a guard with the decedent during his entire stay at the hospital and would be with the decedent until I arrived.

CHIEF DEPUTY CORONER K. AH YOU	DEPUTY CORONER E. HAWTHORNE SR24	SH/S654	Page 1
SUPERVISOR APPROVING	INVESTIGATING OFFICER		

**SHERIFF'S DEPARTMENT**  
**County of Stanislaus**

DATE 4/23/09	O T	INCIDENT REPORT	FOLLOW-UP REPORT	FILE NO. S09-15518
-----------------	--------	--------------------	---------------------	-----------------------

VICTIM (AS LISTED ON ORIGINAL REPORT) PRESCOTT, CRAIG EDWARD	LOCATION OF OCCURRENCE DOCTORS MEDICAL CENTER, MODESTO, CA
---	---

I was informed the decedent was being transported to the holding area at approximately 1940 hours. I met DMC's security guard in the holding area and took possession of the decedent. The decedent was in a white hospital body bag. I observed the decedent to be a black male adult lying supine with no clothing. No post mortem rigidity or lividity was observed. The decedent was warm to the touch. I observed what appeared to be abrasions to his right knee/thigh area. No other injuries were observed. Multiple medical devices were attached and/or inserted. After checking the decedent's hospital identification band on his left wrist I transported him to the radiology department in DMC's emergency room and requested full body x-rays. Copies of the x-rays were obtained on compact disc. Before leaving the hospital the decedent was double bagged into a blue body bag which was secured with flex cuff #06336. The decedent was then loaded and secured in the coroner's van for transport to the coroner's facility.

Once at the coroner's facility the decedent was placed in the refrigeration unit.

The following day fingerprints and photographs were taken and an identification band was placed on his right wrist at the time of autopsy. The autopsy was performed by Dr. Carpenter at 0940 hours on 4/14/09. The decedent's cause of death is pending toxicology and histology. The decedent's manner of death is pending investigation.

It was requested of the coroner's facility by Stanislaus County Sheriff Detective Hedrick and Sgt Kiely to preserve the decedent's brain for study on excited delirium. However, when I contacted the University of Miami Brain program, who performs the studies, I was advised that because the decedent had been on life support, it would be of no use to do the study. I relayed this information regarding the study to Detective Hatfield and Sgt. Kiely.

The decedent's property was brought to the coroner's facility from the men's jail on 4/14/09. It included a wallet with his California ID, a \$50.00 money order, a pair of black and red shorts and gray shoes. The decedent's property was logged and secured in the property room for release to his family.

The decedent's family chose Salas Bros. Funeral Chapel to handle funeral arrangements and on 4/15/09 at 1525 hours, the decedent was released to a representative of Salas Bros.

On 4/16/09 the decedent's property was released to his wife, Rachel Prescott.

Nothing further to report at this time.  
 End of report.

<b>CONTROLLED DOCUMENT</b>	
DUPLICATION OR REISSUANCE CONTROLLED BY LAW	
CHIEF DEPUTY CORONER K. AH YOU	DEPUTY CORONER E. HAWTHORNE SR24 SH/S654 Released to: <u>Cpt. Beck</u>
SUPERVISOR APPROVING	INVESTIGATING OFFICER
By <u>SH</u> Date <u>4/30/09</u>	

CHIEF DEPUTY CORONER K. AH YOU	DEPUTY CORONER E. HAWTHORNE SR24 SH/S654 Released to: <u>Cpt. Beck</u>	Page 2
SUPERVISOR APPROVING	INVESTIGATING OFFICER	
By <u>SH</u> Date <u>4/30/09</u>		

FOLLOW-UP ---CONTINUATION SHEET

**SHERIFF'S DEPARTMENT**  
**County of Stanislaus**

DATE 5/13/09	<input type="checkbox"/> INCIDENT REPORT	<input checked="" type="checkbox"/> FOLLOW-UP REPORT	FILE NO. S09-15518
-----------------	--	--	-----------------------

VICTIM (AS LISTED ON ORIGINAL REPORT) PRESCOTT, CRAIG	LOCATION OF OCCURRENCE DOCTORS MEDICAL CENTER, MODESTO, CA
--	---

**CONTROLLED DOCUMENT**  
 DUPLICATION OR REISSUANCE  
 CONTROLLED BY LAW  
 Released to Cpt. Brock  
 By Elt Date 6/3/09

**CORONER'S REPORT # 09-04-24**

**SYNOPSIS:**

**CORONER'S CASE: FOLLOW-UP REPORT**

**NARRATIVE:**

On 4/13/09 1205 I was notified of the death of Craig Prescott, a black male adult, date of birth 4/7/71 age 38. Kathy Butler an RN, at Doctors Medical Center informed me that the decedent was brought in by ambulance on April 11, 2009 from the Men's downtown jail after being restrained by adult detention staff.

According to Kathy Butler the inmate had been combative, and non compliant while in custody. During that process electric shock devices were used multiple times to subdue the inmate. According to Kathy, the decedent had been administered Ativan by medical staff at the jail. At some point Prescott, C. went apneic, and unresponsive in front of the deputies during transport to a safety cell. The decedent was on life support and had been pronounced brain dead by two separate physicians. Kathy stated family had not been notified of the death as of this time. I placed a coroner's hold on the decedent per standard coroner protocol.

I placed a call to Stanislaus County Sheriff Detective Sgt. Kiely with the homicide unit for clarification and further information on this case. Sgt. Kelly stated that he had been briefed on this case, and that their unit would be further investigating this incident. Sgt. Kiely stated he did not need to be present when the family was notified. I also spoke with Sgt. John Campbell of the Men's Jail who informed me that a guard would be present with the decedent until we arrived and would supply us with further information and the reports regarding this incident.

After conferring with Deputy Coroner Elizabeth Hawthorne we explained to the hospital that the family must be notified immediately by the hospital staff, so that the attending physician could answer all questions and relay pertinent medical information regarding the death of Craig Prescott and provide visitation with family. I transferred the case to Hawthorne.

Please refer to her report for further details.

Nothing further to report at this time.

CHIEF DEPUTY CORONER K. AH YOU <i>[Signature]</i>	DEPUTY CORONER T. MENDE S777	Page 1
SUPERVISOR APPROVING	INVESTIGATING OFFICER	

**SHERIFF'S DEPARTMENT**  
**County of Stanislaus**

DATE 5/13/09	INCIDENT REPORT	<input checked="" type="checkbox"/> FOLLOW-UP REPORT	FILE NO. S09-15518
-----------------	--------------------	---	-----------------------

VICTIM (AS LISTED ON ORIGINAL REPORT) PRESCOTT, CRAIG	LOCATION OF OCCURRENCE DOCTORS MEDICAL CENTER, MODESTO, CA
--	---

End of Report.

CONTROLLED DOCUMENT  
EVIDENCE OR REISSUANCE  
CONTROLLED BY LAW  
Released to Cpt. Brock  
By EA Date 6/3/09

CHIEF DEPUTY CORONER K. AH YOU <i>[Signature]</i>	DEPUTY CORONER T. MENDE S777	Page 2
--	------------------------------	--------

SUPERVISOR APPROVING

INVESTIGATING OFFICER

# STANISLAUS COUNTY CORONER'S MEMORANDUM

C.C. # 09-04-24  
S/O File# S09-15518  
Notified By: Kathy @DMC  
Date/Time 4/13/09 1205

Decedent: PRESCOTT Craig Edward Race: B Sex: M DOB: 4/7/71 Age: 38  
Last First Middle

Residence: 4336 Claus Road, Riverbank Phone: 578-4698 Marr: X Sgl:     Div:     Wid:    

Occupation:     Bus. Address:     Phone:      
Veteran: Yes:     No:     Branch Service:     Dis. Date:     Type:     SS#:    

Next of Kin (1): Rachel Prescott Relation: wife

Address: same Phone: same

Next of Kin (2):     Relation:    

Address:     Phone:    

Family Notified By: present at hospital Date/Time:    

Place of Death: DMC Date/Time: 4/13/09 1120

Pronounced/Found By: Dr. Kamathan Address:     Phone:    

Family Physician:     Phone:     Date Last Seen:    

Admitting Diagnosis: cardiac/respiratory arrest

Last Seen Alive By: Hospital Staff Address:     Date/Time:    

Identified By: Hospital Staff Address:     Date/Time:    

Property: Booked:     Released:     None: X House Sealed: Yes:     No: X

Address: Accident Homicide Suicide 1115 H Street, Modesto, 95354 Date/Time:      
(Exact Location)

Auto - Industrial - Other: in-custody altercation Pass:     Driver:     Ped:    

Other Agencies: S/O Detective Hedrick Date/Time Arriv'd:     Report #:    

Ambulance Co./Fire Dept.: AMR Date/Time Arrived: 4/9/2009

Mortuary: Salas Written:  Verbal:  By:    

Disposition: Coroner Case: X Reportable:     No Case:     P.A.:     Storage: YES

Reason: In-Custody Death

Reviewed By: Chief Dep. K. Ah You Elizabeth Hawthorne #520  
(Deputy Coroner)

Dispo.     Released to: Cpt Beck Date/Time: 4/13/09

Autopsy:     Medical Exam:     Sign-Out:    

Reportable:     No Case:     P.A.:     Storage: YES

**CONTROLLED DOCUMENT**

DUPLICATION OR REISSUANCE  
CONTROLLED BY LAW

Released to: Cpt Beck Elizabeth Hawthorne #520  
(Deputy Coroner)

By: elt Date: 4/13/09 Date/Time: 4/13/09

Sign-Out: